

Managing ONJ

Identification of ONJ by an oral healthcare professional at an early stage means that the majority of patients can be managed conservatively using the following treatments:^{6,8,16}

- maintenance of optimal oral hygiene
- elimination of active dental and periodontal disease
- topical antibacterial mouth rinses
- systemic antibiotic therapy.

This approach will resolve the majority of early-stage cases or provide long-term symptomatic relief.^{6,20,21} For non-responsive ONJ lesions, consultation by an oral health specialist is required in order to assess if surgery (debridement and/or resection) may be effective.^{6,22,23}

There is a lack of data supporting discontinuation of bone-protective therapy (a 'drug holiday').⁸ If ONJ develops, the patient's oncologist may consider discontinuing the therapy until soft tissue closure is achieved; in such cases, the risk of skeletal-related events if therapy is stopped should also be assessed.^{8,24} A multidisciplinary management plan should be set up in close collaboration with the patient's clinician.^{1,2,16}

Key questions

- Has your patient had any recent changes in medication?
- Is your patient currently undergoing treatment for cancer, osteoporosis or bone loss?
- Does your patient have any additional risk factors for ONJ?

Take-home messages

- ONJ can occur as a complication of high-dose bone-protective therapy used for patients with advanced malignancies involving bone.
 - Patients receiving low-dose bone-protective therapy have a much lower risk of ONJ.
- The risk of ONJ can be reduced by implementing preventive dental measures before starting treatment, maintaining good oral hygiene, ensuring periodic follow-up by dental professionals and avoiding elective invasive procedures during treatment.
- It is important that oral healthcare providers discuss treatment options with the prescribing clinician before conducting any essential invasive dental procedures in a patient receiving bone-protective therapy.
- Early diagnosis enables most cases of ONJ to be managed effectively and conservatively by an experienced and trained dental specialist.

References

1. European Medicines Agency. Zometa® (zoledronic acid) summary of product characteristics. Available from: https://www.ema.europa.eu/en/documents/product-information/zometa-epar-product-information_en.pdf (Accessed 28 September 2020).
2. European Medicines Agency. XGEVA® (denosumab) summary of product characteristics. Available from: https://www.ema.europa.eu/en/documents/product-information/xgeva-epar-product-information_en.pdf (Accessed 28 September 2020).
3. European Medicines Agency. Prolia® (denosumab) summary of product characteristics. Available from: https://www.ema.europa.eu/en/documents/product-information/prolia-epar-product-information_en.pdf (Accessed 28 September 2020).
4. European Medicines Agency. Aclasta® (zoledronic acid) summary of product characteristics. Available from: https://www.ema.europa.eu/en/documents/product-information/aclasta-epar-product-information_en.pdf (Accessed 28 September 2020).
5. European Medicines Agency. Further measures to minimise risk of osteonecrosis of the jaw with bisphosphonate medicine. Available from: <https://www.ema.europa.eu/en/news/further-measures-minimise-risk-osteonecrosis-jaw-bisphosphonate-medicine> (Accessed 28 September 2020).
6. Khan AA *et al.* *J Bone Miner Res* 2015;30:3–23.
7. Sim leW *et al.* *J Clin Endocrinol Metab* 2015;100:3887–93.
8. American Association of Oral and Maxillofacial Surgeons. Medication-related osteonecrosis of the jaw – 2014 update. 2014. Available from: https://www.aaoms.org/docs/govt_affairs/advocacy_white_papers/mronj_position_paper.pdf (Accessed 28 September 2020).
9. Ripamonti CI *et al.* *Ann Oncol* 2009;20:137–45.
10. Dimopoulos MA *et al.* *Ann Oncol* 2009;20:117–20.
11. Saad F *et al.* *Ann Oncol* 2012;23:1341–7.
12. Ficarra G, Beninati F. *Clin Cases Miner Bone Metab* 2007;4:53–7.
13. Ruggiero SL *et al.* *J Oral Maxillofac Surg* 2009;67:2–12.
14. Yamashita J. *J Evid Based Dent Pract* 2012;12:233–47.
15. Barasch A *et al.* *J Dent Res* 2011;90:439–44.
16. Yarom N *et al.* *J Clin Oncol* 2019;37:2270–90.
17. Nicolatou-Galitis O *et al.* *Oral Dis* 2020; Epub 3 Feb 2020.
18. Nicolatou-Galitis O *et al.* *Oral Surg Oral Med Oral Pathol Oral Radiol* 2019;127:117–35.
19. Otto S *et al.* *Cancer Treat Rev* 2018;69:177–87.
20. Bodem JP *et al.* *J Craniomaxillofac Surg* 2015;43:1139–43.
21. Moretti F *et al.* *Oral Surg Oral Med Oral Pathol Oral Radiol Endod* 2011;112:777–82.
22. Lopes RN *et al.* *J Oral Maxillofac Surg* 2015;73:1288–95.
23. Ristow O *et al.* *J Craniomaxillofac Surg* 2015;43:290–3.
24. Gallego L, Junquera L. *Br J Oral Maxillofac Surg* 2009;47:67–8.

This document was reviewed by an ADEE panel in September 2020.

For further information, please visit <https://adee.org/partners/adeeamgen-onj>



Amgen (Europe) GmbH
6343 Risch-Rolkreuz
Switzerland

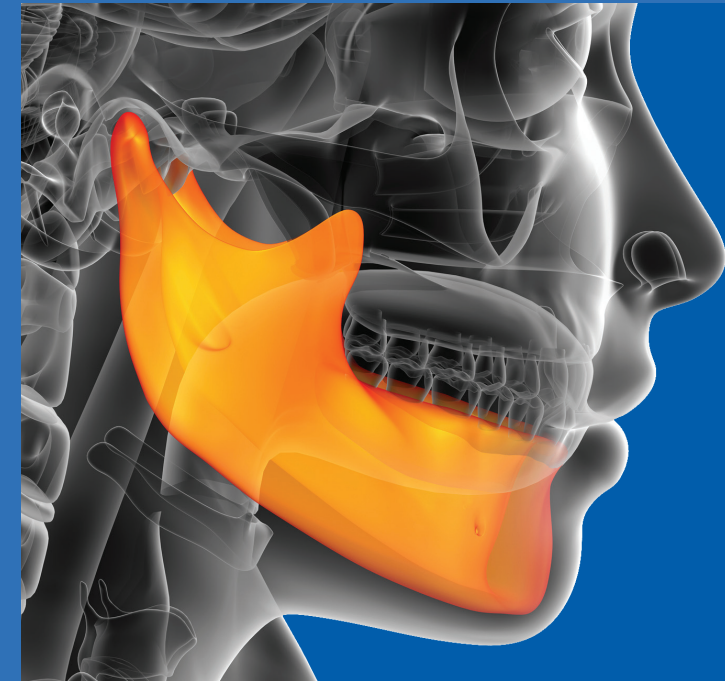
www.amgen.com

©2020 Amgen Inc. All rights reserved

AMGEN®

Job code: SC-EU-AMG162-00623 | Date of preparation: October 2020

Oral healthcare professionals and osteonecrosis of the jaw



By understanding the risk factors for osteonecrosis of the jaw (ONJ) and the steps that can be taken to avoid it, oral healthcare professionals can play a key role in the prevention of this complication in patients receiving bone-protective therapy. It is also essential that all oral healthcare professionals, including dentists, dental specialists and hygienists, are aware of the signs and symptoms so that, when ONJ occurs, diagnoses can be made promptly and patients can be treated effectively and conservatively.

What is ONJ?

ONJ is a bone complication that can be associated with the use of antiresorptive or 'bone-protective' therapy (bisphosphonates or denosumab). These agents are indicated for the prevention of skeletal-related events in patients with advanced malignancies involving bone, and treatment of giant cell tumour of the bone, osteoporosis and bone loss associated with adjuvant cancer treatment or long-term systemic glucocorticoid therapy.¹⁻⁶

Although ONJ can lead to considerable morbidity, there are many steps that can be taken to prevent the condition, in addition to effective management strategies.⁶⁻¹⁰

Accurate diagnosis is crucial because patients receiving bone-protective agents may present with other common clinical conditions, which should not be mistaken for ONJ.

Such conditions include: alveolar osteitis, caries, chronic sclerosing osteomyelitis, fibro-osseous lesions, gingivitis/periodontitis, sinusitis, periapical pathology and temporomandibular joint disorders.⁸

Identifying ONJ

ONJ may present with the following signs and symptoms:^{11,12}

- exposed bone
- paraesthesia in the region of the jaw/gum
- loosening of teeth
- fistulae
- swelling
- exudation
- pain
- soft tissue infection
- halitosis.

ONJ needs to be managed by a specialist experienced in managing ONJ.

ONJ^a is characterised by three main features¹³



An area of exposed jawbone



No healing for more than 8 weeks



No previous craniofacial irradiation

^aONJ related to bone-protective therapy is sometimes referred to as 'medication-related ONJ' or 'MRONJ'

Who is at risk of ONJ?

Patients receiving high-dose bone-protective therapy for the prevention of skeletal-related events in advanced malignancies involving bone are at increased risk. Patients receiving low-dose bone-protective therapy, which is used to treat osteoporosis and bone loss associated with adjuvant cancer treatment or long-term systemic glucocorticoid therapy, have a much lower risk of ONJ.^{3,4,6,8}

Various other factors are associated with an increased risk of ONJ in patients receiving bone-protective therapy.^{1-4,6,11,14-18}

The main risk factors include:



dental disease or poor dental hygiene



invasive dental treatments (e.g. tooth extraction [mainly due to pre-existing gum disease], insertion of dental implants or prostheses, or surgery in the region of the mouth)



cancer therapy (e.g. radiotherapy in the region of the head and neck, chemotherapy, corticosteroid therapy, or previous treatment with bisphosphonates or inhibitors of angiogenesis)



concomitant diseases (e.g. pre-existing dental diseases, cancer, anaemia, infections, diabetes mellitus, immunosuppression or renal failure)



smoking



old age (over 60 years old).

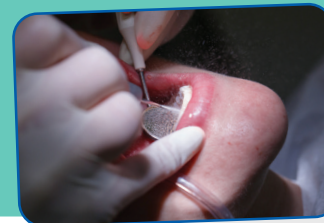How can ONJ be prevented?

Before initiating high-dose bone-protective therapy or low-dose therapy with the presence of additional risk factors, oral healthcare providers and patients should consider the following preventive measures:^{2,8,19}

- removing non-restorable teeth and completing dental surgery (bone-protective therapy should not be initiated until the extraction site wound has healed)
- treating infections in the mouth region
- checking prostheses to ensure good positioning and treating any pressure points that have arisen.

If possible, restorative dental procedures should be completed before the start of treatment. If invasive dental treatment is required while receiving high-dose bone-protective treatment, or if the patient develops dental or periodontal disease that doesn't respond to treatment within a few weeks, they should be referred to a specialist experienced in managing ONJ.

To reduce the risk of ONJ further during treatment with bone-protective therapy, all patients should be encouraged to maintain good oral hygiene, to have dental check-ups (at least every 6 months) and dental treatments as needed (prophylactic dental cleaning, tooth fillings and non-traumatic treatments or prosthetics without bone anchoring may be performed), and to immediately tell their healthcare team, including their oral healthcare provider, about any problems with their mouth or teeth.^{1,2,16,19}



ONJ stages^{8,16}

At risk

Patients who are receiving bone-protective therapy

Increased risk

No clinical evidence of necrotic bone, but non-specific clinical findings and symptoms

Stage 1

Exposed and necrotic bone in asymptomatic patients without evidence of infection

Stage 2

Exposed and necrotic bone or fistulae in patients with infection, pain and erythema in the region of exposed bone

Stage 3

Exposed and necrotic bone in patients with infection and additional complications (exposed and necrotic bone extending beyond the alveolar ridge, pathologic fracture, extraoral fistulae, oroantral/oronasal fistulae or osteolysis)